

Granulomatosis with Polyangiitis: Integrating Immunopathogenesis, Multisystem Clinical Spectrum, and Miasmatic Interpretation

Subhadeep Chakraborty¹, Mukesh Maity¹, Sinchan Das¹

¹Assistant Professor, Department of Allied Health Sciences, Barasat, Kolkata, West Bengal 700125

Abstract

Background: Wegener's Granulomatosis is a rare, potentially life-threatening autoimmune vasculitis characterized by necrotizing granulomatous inflammation of small- to medium-sized blood vessels. The disease predominantly affects the upper respiratory tract, lungs, and kidneys and belongs to the spectrum of antineutrophil cytoplasmic antibody (ANCA)-associated vasculitis.

Objective: To comprehensively review the epidemiology, aetiopathogenesis, pathophysiology, clinical manifestations, investigations, histopathology, differential diagnosis, complications, prognosis, and management of Wegener's granulomatosis, with an additional integrative perspective through miasmatic analysis and remedy correlation.

Methods: A narrative, descriptive review was conducted using standard authoritative medical textbooks and contemporary literature. Epidemiological data, immunopathogenic mechanisms involving PR3-ANCA and MPO-ANCA, clinical features, and diagnostic criteria were synthesized. Histopathological findings from pulmonary and renal involvement were emphasized. Management strategies were reviewed in accordance with recent EULAR recommendations. A complementary miasmatic interpretation was incorporated to correlate classical homoeopathic concepts with disease pathology.

Results: Wegener's granulomatosis exhibits an annual incidence of 5–20 cases per million populations, with a peak occurrence between 40 and 65 years of age. PR3-ANCA positivity is observed in the majority of generalized cases. The disease manifests with a characteristic triad of upper airway disease, pulmonary involvement, and rapidly progressive glomerulonephritis. Histopathology reveals necrotizing granulomatous inflammation with pauci-immune crescentic glomerulonephritis. Early diagnosis and immunosuppressive

therapy significantly improve survival, exceeding 80–90% at five years. From a miasmatic standpoint, the disease demonstrates predominant syphilitic pathology with syco-syphilitic overlap.

Conclusion: Wegener's granulomatosis remains a complex multisystem disorder requiring early recognition and aggressive management to prevent irreversible organ damage. Integrating conventional immunopathological understanding with holistic interpretative frameworks may enhance conceptual clarity and educational value. Continued advancements in diagnostic and therapeutic strategies have substantially improved patient outcomes.

Keywords: Granulomatosis with polyangiitis; Wegener's granulomatosis; ANCA-associated vasculitis; PR3-ANCA; necrotizing granuloma; Miasmatic analysis

Introduction:

"Wegener's granulomatosis, currently designated as Granulomatosis with Polyangiitis (GPA), is a rare systemic autoimmune vasculitis characterized by necrotizing granulomatous inflammation of small- to medium-sized blood vessels, predominantly affecting the upper respiratory tract, lungs, and kidneys (Jameson et al., 2022; Ralston et al., 2022). The disease belongs to the spectrum of antineutrophil cytoplasmic antibody (ANCA)-associated vasculitis and, if left untreated, is associated with high morbidity and mortality due to progressive organ damage, particularly renal failure and pulmonary haemorrhage (Kumar et al., 2021).

The immunopathogenesis of GPA involves a complex interplay between genetic susceptibility, environmental triggers, and dysregulated innate and adaptive immune responses. Central to disease development is the production of PR3-ANCA and, less frequently, MPO-ANCA, which activate neutrophils and promote endothelial injury through degranulation, release of reactive oxygen species, and formation of neutrophil extracellular traps (NETs) (Falk & Jennette, 2010; Kallenberg, 2014).

Definition

Wegener's granulomatosis, also known as the Granulomatosis with Polyangiitis (GPA), is a chronic, multisystem autoimmune disease characterized by necrotizing granulomatous inflammation and vasculitis of small- to medium-sized blood vessels, predominantly affecting the upper respiratory tract, lungs, and kidneys. GPA is part of a spectrum of disorders known as antineutrophil cytoplasmic antibody (ANCA)-associated vasculitis.

Epidemiology:

Epidemiological Parameter	Description
Disease frequency	Rare systemic autoimmune vasculitis
Annual incidence	5–20 cases per million population
Prevalence	25–160 cases per million population
Age distribution	Occurs at any age; peak incidence between 40–65 years
Paediatric occurrence	Rare but well documented
Sex distribution	Males and females are affected almost equally, with a slight male predominance
Ethnic distribution	More common in White/Caucasian populations
Geographic distribution	Higher incidence in Northern Europe, UK, Scandinavia, and North America; lower reported incidence in Asia and Africa
Indian scenario	Considered uncommon; likely underdiagnosed (API)
Genetic associations	HLA-DP alleles; PR3 gene polymorphisms
Familial occurrence	Rare; no clear hereditary pattern
Environmental associations	Chronic nasal carriage of <i>Staphylococcus aureus</i> ; possible association with silica exposure
ANCA positivity	c-ANCA (PR3-ANCA) positive in ~80–90% of generalized disease
ANCA epidemiology	Lower positivity in limited disease; titres correlate with disease activity and relapse
Natural course (untreated)	>90% mortality within 1–2 years
Survival with treatment	5-year survival exceeds 80–90%

Table: 1 Epidemiology of Wegner’s Granulomatosis (Munjaj, 2019; Ralstonetal, 2022)

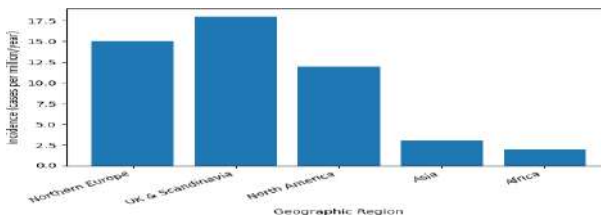


Figure: 1 Epidemiology of Wegner's Granulomatosis

- Y-axis: Incidence (cases per million per year)
- X-axis: Geographic regions
- Concept shown: Higher incidence in Northern Europe, UK/Scandinavia, and North America, with lower reported incidence in Asia and Africa

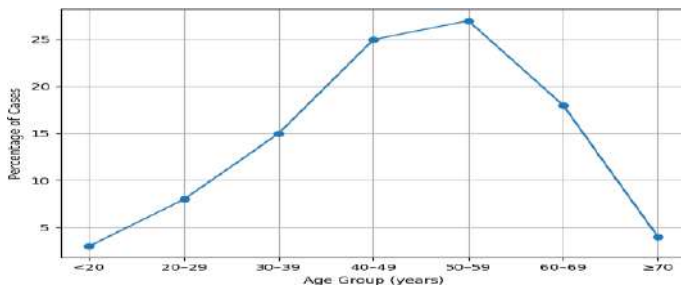


Figure 2 Age Distribution of Wegener's Granulomatosis

- X-axis: Age groups (years)
- Y-axis: Percentage of cases
- Peak incidence: 40–59 years
- Lower frequency: Children and elderly

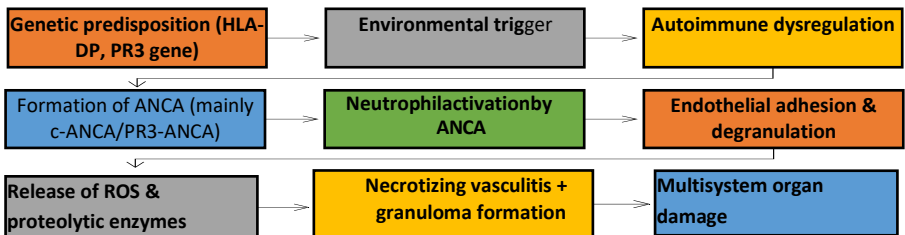
Etiology: The exact aetiological factors are still not completely understood, but it is obvious that Wegener's granulomatosis is sharing a multisectoral aetiological framework, which includes the involvement of Antineutrophil Cytoplasmic Antibody in the occurrence of Wegener's Granulomatosis. Defective immune-regulatory responses to environmental factors, such as infection or autoantigens, can lead to excessive production of cytokines, which in turn may develop inflammatory granulomatous vascular lesions. Before going to the further discussion, we should discuss two major types of antineutrophil cytoplasmic antibodies in brief. The two major types of antineutrophil cytoplasmic antibodies are: Anti-proteinase 3 (PR3) and Anti-myeloperoxidase (MPO), which are playing crucial roles in the disease process. An antineutrophil cytoplasmic antibody in Wegener's Granulomatosis typically reacts with PR3, a serine proteinase prevalent in neutrophil granulocytes. When antineutrophil cytoplasmic antibodies bind to PR3, it activates neutrophils, increasing their adherence to the endothelium and triggering degranulation, which can damage endothelial cells. Neutrophils from Wegener's granulomatosis cases are more likely to produce neutrophil extracellular traps and exhibit lower DNase I activity, leading to decreased clearance of neutrophil extracellular traps. Neutrophil extracellular traps are composed of decondensed chromatin and intracellular granules that capture cell components. Anti-PR3 binds to neutrophils, leading to degranulation, reactive oxygen species, adhesion to endothelial cells, and secretion of pro-inflammatory cytokines, especially interleukin-8. Although neutrophils are an integral part of innate immunity, adaptive immunity responses are also significant. B-cells specific to PR-3 are associated with disease activity and risk of relapse.

Cause	Description	
Genetic Cause	<ul style="list-style-type: none"> • A defective allele for alpha-1 antitrypsin • Cytotoxic T-lymphocyte-associated protein 4 (CTLA-4), which is involved in T-cell activation • PR3 gene • Major histocompatibility complex, class II, DP alpha-1 (HLA-DP) gene • Certain types of FC gamma receptor IIIb on the surface of neutrophils and macrocytes or monocytes 	
Infections	Viral	Hepatitis C virus, Cytomegalovirus, Epstein-Barr virus, and Parvovirus
	Bacterial	Colonization with <i>Staphylococcus aureus</i>
Drugs	<ul style="list-style-type: none"> • Hydralazine • Propylthiouracil and methimazole • Allopurinol • Sulfasalazine • Minocycline • Penicillamine • Rifampicin • Aminoguanidine • Sofosbuvir • Anti-tumour necrosis factor-alpha therapy for rheumatoid arthritis and ankylosing spondylitis 	

Table2: Aetiological Factors of Wegener’s Granulomatosis

Pathogenesis:

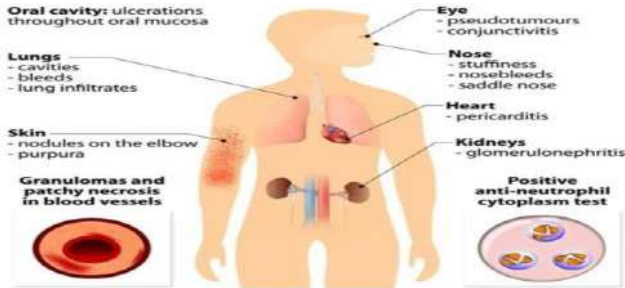
The Wegener’s granulomatosis shares a complex multisectoral pathogenetic pathway with antineutrophil cytoplasmic antibodies, neutrophils, T & B-lymphocytes, monocytes, endothelial cells & the alternative complement pathway. The pathogenic hallmark is the loss of immunological T and B cell tolerance to neutrophilic proteins, namely Proteinase 3 (PR3) or Myeloperoxidase (MPO). This process occurs alongside risk factors such as genetic background, age, environmental factors, and inflammation and/or infection.



Flowchart: 1 Pathogenesis of Wegener’s Granulomatosis

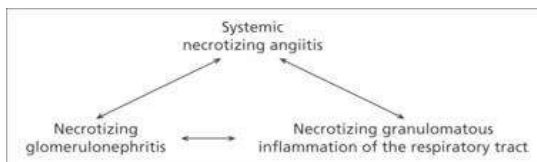
Clinical Manifestations:

System Involved	Clinical Manifestations
Constitutional	Fever, malaise, fatigue, weight loss, anorexia, night sweats
Upper respiratory tract (ENT)	Chronic sinusitis, nasal obstruction, nasal crusting, epistaxis, nasal ulcers, septal perforation, saddle-nose deformity, otitis media, hearing loss
Lower respiratory tract (Lungs)	Cough, haemoptysis, dyspnoea, pleuritic chest pain, pulmonary nodules, cavitary lesions, diffuse alveolar haemorrhage
Renal system	Haematuria, proteinuria, rapidly progressive glomerulonephritis, hypertension, acute or chronic renal failure
Skin	Palpable purpura, petechiae, ulcers, nodules, livedo reticularis
Eyes	Conjunctivitis, episcleritis, scleritis, uveitis, orbital pseudotumor, proptosis
Musculoskeletal	Arthralgia, inflammatory arthritis, myalgia
Nervous system	Mononeuritis multiplex, peripheral neuropathy, cranial nerve palsies
Cardiovascular	Pericarditis, myocarditis, coronary arteritis (rare)
Gastrointestinal tract	Abdominal pain, gastrointestinal bleeding, ischemic bowel (rare)
Genitourinary	Epididymitis, orchitis (rare)
Others	Subglottic stenosis, hoarseness of voice



Classic Triad of Wegener’s Granulomatosis:

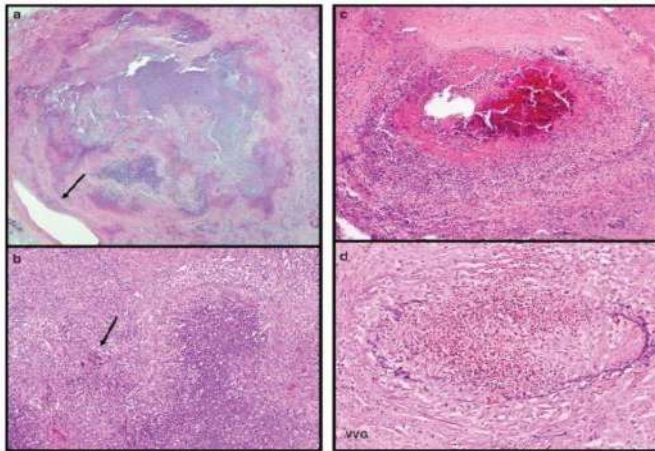
- The classic triad of Wegener’s granulomatosis involves: Upper respiratory tract, including sinusitis, crusting rhinitis, saddle nose deformity, otitis media, mastoiditis, and hearing loss, and lower respiratory tract, such as lung nodules and alveolar haemorrhage
- Systemic vasculitis
- Kidney involvement, such as glomerulonephritis



Histopathology of Wegner’s Granulomatosis:

Organs Involved	Histologic Features
Lungs	<ul style="list-style-type: none"> ✓ Granulomas surrounded by palisading histiocytes and giant cells with central necrosis. ✓ The central necrosis leads to liquefaction or coagulative necrosis in the lungs with profuse eosinophils and multinucleated giant cells. Necrotizing or granulomatous vasculitis is found in small arteries and veins, and the lumens can be occluded by granulomas or thrombi. ✓ CT scans and 18-F-fluorodeoxyglucose positron emission/CT scans can also be used to identify active lesions to increase the biopsy yield
Kidneys	<p>Light microscopy shows necrotizing and crescentic glomerulonephritis. Cellular, microcellular, and fibrous crescents may all be present, representing different stages of disease progression. Immunofluorescence staining is typically negative or very light for immunoglobulins (Ig) or complement. If present, the small amounts are more likely to be present in a segmental distribution (unlike the diffuse distribution of immune complex glomerulonephritis).</p>

Table3: Histology of Wegner’s Granulomatosis

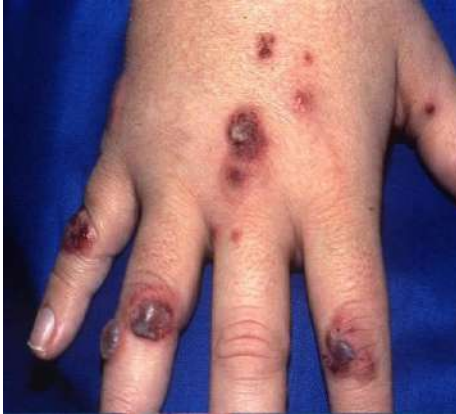

- (a). Wegner's granulomatosis is characterized by 'dirty' basophilic necrosis with irregular geographic necrosis. This prompts the search for necrotizing vasculitis in vessels more peripheral to the necrosis (arrow; H&E, ×20).
- (b). The necrosis is rimmed by palisading histiocytes, and scattered multinucleated giant cells are easily seen even at low power because of the hyperchromatic nuclei (arrow; H&E, ×100).
- (c). Vessels with true necrotizing vasculitis display fibrinoid necrosis of the media with admixed necrotic neutrophils.
- (d). An elastic stain helps in assessing transmural necrosis and inflammation of a portion of the vascular wall (H&E, ×100 and VVG, ×200).

Investigations:

Category of Investigation	Specific Test	Probable/Expected Findings (Textbook-aligned)	Clinical Significance
Haematological	Complete blood count (CBC)	Normocytic normochromic anaemia; leucocytosis; thrombocytosis	Reflects chronic inflammation and disease activity
	ESR	Markedly elevated	Indicator of active disease
	CRP	Elevated	Correlates with disease severity
Renal investigations	Urine routine & microscopy	Haematuria, proteinuria, red blood cell casts	Suggests glomerulonephritis
	Serum creatinine	Elevated	Indicates renal involvement and prognosis
	Blood urea	Elevated in advanced disease	Renal impairment
Immunological tests	c-ANCA (PR3-ANCA)	Positive in ~80–90% of generalized GPA	Highly sensitive and specific
	p-ANCA (MPO-ANCA)	Occasionally positive	Seen in limited/overlap cases
	ANA, RF	Usually negative or low titre	Helps exclude SLE or RA
Biochemical tests	Serum electrolytes	May show abnormalities secondary to renal failure	Assesses metabolic status
	Liver function tests	Usually normal	Baseline before immunosuppression
Radiological – Chest	Chest X-ray	Pulmonary nodules, cavitary lesions, infiltrates	Suggests lung involvement
	HRCT chest	Nodules, cavitation, ground-glass opacities, alveolar haemorrhage	More sensitive than X-ray
Radiological – ENT	X-ray / CT of paranasal sinuses	Mucosal thickening, sinus opacification, bone erosion	Common early manifestation
Renal imaging	Ultrasound kidney	Normal or small kidneys in chronic disease	Assesses chronicity
Histopathology (Gold standard)	Nasal/lung biopsy	Necrotizing granulomatous inflammation with vasculitis	Diagnostic confirmation
	Renal biopsy	Pauci-immune crescentic glomerulonephritis	Confirms renal involvement
Bronchoscopy	BAL (if haemoptysis)	Hemosiderin-laden macrophages	Indicates alveolar haemorrhage
Microbiological tests	Sputum AFB, culture	Negative	Helps rule out tuberculosis
Other investigations	ECG / Echocardiography	Usually normal; may show pericarditis (rare)	Cardiac involvement
	Audiometry	Conductive or sensorineural hearing loss	ENT complications

Table: 4 Investigations of Wegner's Granulomatosis



Pic 1 Dermatological Manifestation of Wegner's Granulomatosis

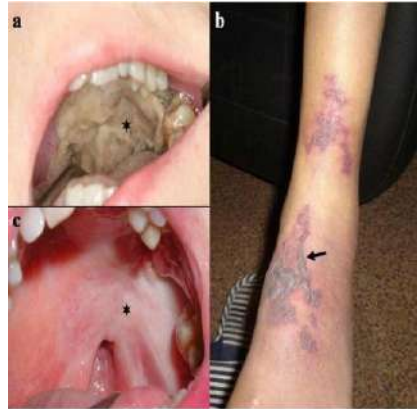
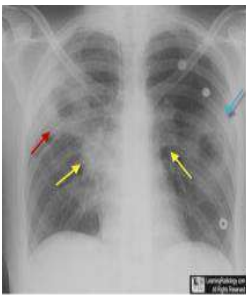
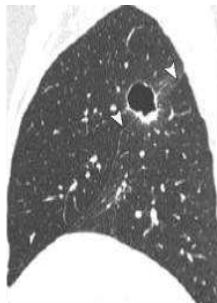


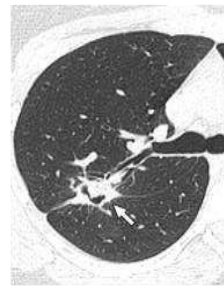Fig. 2. a. Note the left palatal ulcer (asterisk). b. Purpuric eruption on the lower part of the leg (arrow). c. Note the right palatal ulcer (asterisk).



Pic 3



Pic 4



Pic 5

Pic 3: Chest Radiograph is showing cavitations, **Pic 4:** Sagittal high-resolution CT image shows cavity crossing major fissure (arrowheads) and halo of ground-glass opacity surrounding nodule, representing haemorrhage. **Pic 5:** Transverse high-resolution CT image shows Cavitory nodule in right lung (arrow).

Differential Diagnosis:

Condition	Differentiating Feature
Microscopic polyangiitis	No granuloma; p-ANCA positive
Churg–Strauss syndrome	Asthma; eosinophilia
Tuberculosis	Caseating granulomas
Sarcoidosis	Non-caseating granulomas
Goodpasture syndrome	Anti-GBM antibodies
Systemic lupus erythematosus	Immune complex deposition

Table 5: Differential Diagnosis

Miasmatic Analysis:

Clinical/Pathological Feature	Psoric	Sycotic	Syphilitic
Autoimmune dysregulation	✓ (functional disturbance)	✓	✓
Chronicity of disease	✓	✓	✓
Granuloma formation	✗	✓ (proliferation)	✓ (destructive granuloma)
Necrotizing vasculitis	✗	✗	✓✓✓
Tissue destruction	✗	✗	✓✓✓
Ulceration of nasal septum	✗	✗	✓✓✓
Saddle-nose deformity	✗	✗	✓✓✓
Cavitary lung lesions	✗	✗	✓✓
Rapidly progressive GN	✗	✗	✓✓✓
Haemorrhage (epistaxis, haemoptysis)	✗	✗	✓✓
Fibrosis/scarring (late stage)	✗	✓	✓
Relapsing course	✓	✓✓	✓
Resistance to treatment	✗	✓	✓✓

Table: 6 Miasmatic Analysis of Wegener's Disease

Miasmatic Diagnosis: The Wegener's Granulomatosis is exhibiting strong predominance towards the Syphilitic miasm with Syco-syphilitic overlaying & Psora is playing a non-specific role.

Homoeopathic Therapeutics:**Psoric Group of Remedies:**

Remedy	Sycotic Indications
Thuja occidentalis	Fundamental sycosis, overgrowth
Medorrhinum	Hereditary sycosis, excess
Natrum sulphuricum	Infiltration, damp-related complaints
Calcarea sulphurica	Suppuration, non-healing inflammation
Silicea	Chronic abscesses, expulsion of pus
Hepar sulphuris	Suppuration, hypersensitivity
Nitric acid	Syco-syphilitic overlap (fissures, ulceration)

Sycotic Group of Remedies:

Remedy	Psoric Indications
Sulphur	Fundamental psora, hypersensitivity, heat, burning
Psorinum	Extreme weakness, fear of disease, lack of reaction
Calcarea carbonica	Anxiety about health, insecurity, weakness within
Lycopodium	Lack of confidence, digestive weakness
Phosphorus	Sensitivity, fear, haemorrhagic tendency
Natrum muriaticum	Grief, emotional sensitivity, reserved nature
Pulsatilla	Emotional dependency, changeable symptoms

Comparative Miasm-Remedy Chart:

Aspect	Psora	Sycosis	Syphilis
Core pathology	Functional disorder	Overgrowth / infiltration	Destruction
Nature of disease	Reversible	Persistent, recurrent	Irreversible
Tissue change	Minimal	Thickening, swelling	Ulceration, necrosis
Dominant process	Hypersensitivity	Excess & encroachment	Degeneration
Mental state	Anxiety, fear	Possessive, secretive	Despair, hopelessness
Typical remedies	Sulphur, Calc carb, Nat mur	Thuja, Medorrhinum, Silicea	Mercurius, Aurum, Nit-ac
Disease examples	Allergies, functional disorders	Warts, abscesses, granulomas	Ulcers, necrosis, cavitation
Response to treatment	Rapid improvement	Improvement after discharge	Slow, guarded

Non-Homoeopathic Management:

The following are key points from the 2022 **EULAR recommendations** for managing ANCA-associated vasculitis (AAV).

Remission Induction

- **Organ/Life-Threatening GPA (and MPA):**
 - Induce remission with **glucocorticoids** and either **rituximab** or **cyclophosphamide**.
 - **Rituximab** is preferred for relapsing disease. No significant differences have been found between 2-dose and 4-dose rituximab infusions.
- **Non-Organ/Life-Threatening GPA:** * Induce remission with **glucocorticoids** and **rituximab**.
 - In some cases, **methotrexate** and **mycophenolate mofetil** can be substituted for rituximab.

- **Cyclophosphamide is not preferred** due to increased adverse effects, although it is equally effective.
- A lower dose of **prednisolone** (0.5 mg/kg/d) can also be considered.
- **Glucocorticoid Regimen:** * The induction regimen should use oral glucocorticoids at a dose of **50 to 75 mg** of prednisolone daily (weight-dependent).
 - Prednisolone should be tapered to **5 mg daily** over 4 to 5 months.
- **Avacopan:** * An oral **C5a receptor antagonist** that helps block neutrophil attraction and activation.
 - The **ADVOCATE trial** demonstrated that avacopan can be used to induce remission along with rituximab or cyclophosphamide, effectively reducing glucocorticoid exposure.
 - It was FDA-approved in 2021 for severe ANCA-associated vasculitis.

Advanced Interventions & Maintenance

- **Plasma Exchange (PLEX):** * Can be used to induce remission in patients with glomerulonephritis and a **creatinine level > 3.39 mg/dL** (300 $\mu\text{mol/L}$).
 - Routine use for alveolar haemorrhage is **not recommended**, but it is often used as **salvage therapy** for patients with creatinine > **5.7 mg/dL**.
 - A meta-analysis suggests that while PLEX may reduce the risk of end-stage renal disease, it increases the risk of **infections** within the first year.
- **Maintenance of Remission:** * **Rituximab** is recommended. **Azathioprine** or **methotrexate** can be considered, but only for patients with **eGFR > 60 mL/min/1.73m²**.
 - **Duration:** For new-onset disease, maintenance should continue for **24 to 48 months** after remission. Longer treatment is considered for relapsing disease.

Monitoring & Prophylaxis

- **Clinical Assessment:** Treatment decisions should be guided by clinical assessment rather than **ANCA** or **CD19+ B-cell levels**.
- **Safety:** If rituximab is used, **serum immunoglobulin levels** should be measured before each dose.
- **Prophylaxis:** For patients on rituximab, cyclophosphamide, or high-dose glucocorticoids, prophylaxis with **trimethoprim-sulfamethoxazole** should be administered to prevent *Pneumocystis jirovecii* pneumonia.

Prognosis:

A study found that after a median follow-up of 28 months, patients with a urine protein-to-creatinine ratio of more than 0.05 g/mmol were significantly associated with a risk of kidney failure and death. Persistent haematuria was also associated with worse outcomes, although to a lesser extent. GPA is associated with significant morbidity and mortality either due to irreversible organ dysfunction or due to the consequences of intensive/prolonged use of glucocorticoids and immunosuppressive agents. The average life expectancy for a patient with GPA without any treatment is 5 months, with a 1-year survival rate of less than 20%. More than 80% of treated patients have recently survived at least 8 to 9 years. This improvement in survival rates is particularly notable as the disease primarily affects individuals older than 65. With advances in treatment, patients also have a higher long-term survival rate and have been able to lead a relatively normal life.

Complications:

System	Complications	Remarks/Exam Notes
Renal	Rapidly progressive glomerulonephritis, chronic kidney disease, end-stage renal disease (ESRD), hypertension	Most important prognostic determinant
Respiratory – Upper airway	Nasal septal perforation, saddle-nose deformity, chronic sinusitis, subglottic stenosis	Subglottic stenosis may cause stridor & airway obstruction
Respiratory – Lungs	Pulmonary haemorrhage, respiratory failure, cavitary lung lesions, secondary infection	Pulmonary haemorrhage is life-threatening
Ear (ENT)	Chronic otitis media, conductive or sensorineural hearing loss	Due to granulomatous inflammation
Ocular	Scleritis, episcleritis, uveitis, vision loss, orbital pseudotumor	Scleritis indicates severe disease
Neurological	Mononeuritis multiplex, peripheral neuropathy, cranial nerve palsies	Due to vasculitis of vasa nervorum
Cardiovascular	Pericarditis, myocarditis, coronary arteritis (rare)	Often subclinical but serious
Skin	Chronic ulcers, scarring, gangrene	Reflects systemic vasculitis
Musculoskeletal	Chronic arthritis, muscle wasting	Secondary to inflammation
Gastrointestinal	Ischemic bowel, GI bleeding (rare)	Seen in severe systemic disease
Genitourinary	Epididymitis, orchitis (rare)	Uncommon but described
Treatment-related	Infections (opportunistic), cytopenias, infertility, haemorrhagic cystitis, malignancy	Cyclophosphamide-related
Disease course	Relapse, refractory disease	Relapse common even after remission
Mortality-related	Death due to renal failure, pulmonary haemorrhage, sepsis	Infection is a major late cause

Table: 7 Complications of Wegner's Granulomatosis

References:

1. Jameson JL, Fauci AS, Kasper DL, Hauser SL, Longo DL, Loscalzo J, editors. Harrison's principles of internal medicine. 21st ed. McGraw-Hill Education; 2022.
2. Kumar V, Abbas AK, Aster JC. Robbins and Cotran pathologic basis of disease. 10th ed. Elsevier; 2021.
3. Ralston SH, Penman ID, Strachan MWJ, Hobson RP, editors. Davidson's principles and practice of medicine. 24th ed. Elsevier; 2022.
4. Munjal YP, editor. API textbook of medicine. 10th ed. Jaypee Brothers Medical Publishers; 2019.
5. Jennette JC, Falk RJ, Bacon PA, et al. 2012 revised International Chapel Hill Consensus Conference nomenclature of vasculitides. *Arthritis Rheum.* 2013;65(1):1–11.
6. Yates M, Watts RA, Bajema IM, et al. EULAR/ERA-EDTA recommendations for the management of ANCA-associated vasculitis. *Ann Rheum Dis.* 2016;75(9):1583–1594.
7. Kallenberg CGM. Pathogenesis and treatment of ANCA-associated vasculitides. *Clin Exp Rheumatol.* 2014;32(3 Suppl 82):S7–S10.
8. Falk RJ, Jennette JC. ANCA small-vessel vasculitis. *J Am Soc Nephrol.* 2010;21(5):745–757.